Emerg Radiol (2016) 23:365–375
DOI 10.1007/s10140-016-1390-5

REVIEW ARTICLE

Stress fractures: pathophysiology, clinical presentation, imaging features, and treatment options

George R. Matcuk Jr[1] · Scott R. Mahanty[2] · Matthew R. Skalski[3] · Dakshesh B. Patel[1] · Eric A. White[1] · Christopher J. Gottsegen[4]

Received: 26 January 2016 / Accepted: 9 March 2016 / Published online: 22 March 2016
© American Society of Emergency Radiology 2016

Abstract Stress fracture, in its most inclusive description, includes both fatigue and insufficiency fracture. Fatigue fractures, sometimes equated with the term "stress fractures," are most common in runners and other athletes and typically occur in the lower extremities. These fractures are the result of abnormal, cyclical loading on normal bone leading to local cortical resorption and fracture. Insufficiency fractures are common in elderly populations, secondary to osteoporosis, and are typically located in and around the pelvis. They are a result of normal or traumatic loading on abnormal bone. Subchondral insufficiency fractures of the hip or knee may cause acute pain that may present in the emergency setting. Medial tibial stress syndrome is a type of stress injury of the tibia related to activity and is a clinical syndrome encompassing a range of injuries from stress edema to frank-displaced fracture. Atypical subtrochanteric femoral fracture associated with long-term bisphosphonate therapy is also a recently discovered entity that needs early recognition to prevent progression to a complete fracture. Imaging recommendations for evaluation of stress fractures include initial plain radiographs followed, if necessary, by magnetic resonance imaging (MRI), which is preferred over computed tomography (CT) and bone scintigraphy. Radiographs are the first-line modality and may reveal linear sclerosis and periosteal reaction prior to the development of a frank fracture. MRI is highly sensitive with findings ranging from periosteal edema to bone marrow and intracortical signal abnormality. Additionally, a brief description of relevant clinical management of stress fractures is included.

Keywords Stress fracture · Fatigue fracture · Insufficiency fracture · Subchondral insufficiency fracture · Medial tibial stress syndrome · Bisphosphonate-related atypical subtrochanteric femoral fracture

✉ George R. Matcuk, Jr
matcuk@usc.edu

[1] Department of Radiology, Keck School of Medicine, University of Southern California, Los Angeles, CA 90033, USA

[2] Department of Radiology, University of California San Francisco, San Francisco, CA 94143, USA

[3] Department of Radiology, Southern California University of Health Sciences, Whittier, CA 90604, USA

[4] Department of Radiology, New York University, Langone Medical Center, New York, NY 10016, USA

Introduction

Stress fractures are a common entity encountered across all patient demographics. The first description was in Prussian military recruits as a metatarsal injury from marching—the "march fracture" [1]. The proper definition and pathophysiology of the stress fracture today is best understood as two contrary processes with a similar end result. The *fatigue fracture* is the result of an abnormal load upon normal bone, while the *insufficiency fracture* is the result of normal loading upon abnormal bone. The distinction between these two mechanisms is useful to understand, as the underlying pathophysiology will help predict sites of injury, the correct etiology of the stress fracture, and ultimately a diagnosis that will guide the referring clinician to the correct treatment option. This paper will explore the underlying pathophysiology, presentation, imaging findings, and management of stress fractures for the practicing radiologist and clinician.

Pathophysiology

Stress fractures are categorized by the underlying state of the bony matrix being affected and manifests as either fatigue (normal bone) or insufficiency (osteopenic bone) fractures. The differences between fatigue and insufficiency fractures are summarized in Table 1, and the pathophysiology of each is discussed further in this section.

First, a review of bone science including both bone metabolism and structure is useful to fully understand the disease process of the stress fracture. Lamellar bone predominates in the adult and is composed of cortical (80 %) and cancellous bone (20 %). Cortical bone is found mainly in the diaphyses of the long bones and also comprises the "shell" of the cuboid-like bones such as vertebral bodies. The majority of stress fractures in runners occur in cortical bone. Cancellous bone is found in the metaphyses of long bones and the center of cuboid-like bones. It is less dense, undergoes more rapid turnover, and more stress remodeling than cortical bone [2].

Three major types of bone cells are involved in bone turnover: osteoblasts, osteocytes, and osteoclasts [3]. Their individual roles are essential to understanding stress fractures. The osteoblasts are the builders of bone and line the surface of the bone, primarily producing bone matrix, including type I collagen and osteocalcin. These cells are derived from undifferentiated mesenchymal cells and have receptors for parathyroid hormone (PTH) and 1,25-dihydroxyvitamin D. The osteocytes are former osteoblasts, the veterans of the bone, and have become surrounded by calcified bony matrix. Their role is to maintain bone and extracellular concentrations of calcium and phosphorus. The osteoclast is the destroyer of bony matrix and functions to resorb bone. It is derived from a hematopoietic cell line [4].

Bone is a solid material and behaves similar to materials used in structural engineering such as metal, wood, and plastic. These materials follow Wolff's law. As stress on bone is increased, it begins to deform through the bone's elastic range, but can ultimately return to its original configuration. Stress beyond the elastic range creates microfractures and a persistent plastic deformity. Eventually, these microfractures coalesce into a discontinuity within the cortical bone—a stress fracture. Beyond this is the failure point of bone, which results from increased microfractures and cortical cracks until the failure point is exceeded and catastrophic fracture occurs [5–7].

Fatigue fractures

The fatigue fracture is the result of an abnormal repetitive load upon normal bone and occurs during an abrupt increase in frequency, duration, or intensity of activity when bone resorption (osteoclasts) is greater than replacement (osteoblasts). This type of stress fracture commonly occurs in the young active individual, such as the athlete or military recruit. Contributing risk factors are not mutually exclusive of one another; however, they can be divided into two broad categories: extrinsic and intrinsic factors [2].

Extrinsic factors include training regimen, footwear, training surface, and type of sport. For example, ballet dancers who train for greater than 5 h per day have a significantly greater risk of developing a stress fracture than those who train less [8]. Interestingly, Bennell et al. demonstrated the rates of stress fractures differed in types of sport played. Sprinters, hurdlers, and jumpers develop more foot fractures, while long distance runners have more long bone and pelvic fractures [9, 10]. Intrinsic factors are defined as characteristics of the individual person and include gender, age, race, and overall fitness level, as well as skeletal, muscle, joint, and biomechanical factors [2, 11].

Most studies have concluded that females have a higher incidence of fatigue fractures compared with males. While the etiology of this finding is likely multifactorial, this observation has been partially attributed to the female athlete triad. The triad consists of the interrelated problems of eating disorders, amenorrhea, and osteoporosis, which through a complex interplay of nutritional deficiency, hypothalamic and estrogen abnormalities, as well as delayed menarche leads to reduced bone mineral density and places the female athlete at a significant risk for stress fractures [12–14]. Of course, not all female athletes are categorized as having the triad, but many may be

Table 1 Summary of the differences between fatigue and insufficiency fractures

	Fatigue fractures	Insufficiency fractures
Definition	Fracture resulting from abnormal chronic repetitive stress on normal bone	Fracture secondary to normal stress on abnormally weakened bone
Epidemiology	Young, athletes Females > males	Elderly Low body mass index (BMI) Females > males
Pathophysiology	Abnormal load leads to remodeling; when resorption is greater than replacement a fracture occurs	Normal load on weakened bone (osteopenia or metabolic bone disease)
Common locations	Tibia, fibula, metatarsals, femoral neck, pubic rami, calcaneus, and navicular	Sacrum, pubic rami, superior acetabulum, femoral head, medial femoral condyle

along a spectrum and encompass some of the risk factors. For example, multiple studies have shown that stress fractures are more common in amenorrheic or oligomenorrheic women [9, 10, 15, 16]. Nonetheless, the overlying theme is that active women (e.g., military and female athletes) have a higher incidence of fatigue fractures than men when undergoing similar training regimens [13, 17–19]. Additional gender differences including narrower bone width and a slower neuromuscular response may also be culprits in these observed differences between women and men [20, 21].

Typical locations of fatigue fractures include, in decreasing order of incidence: the tibia (33 %), tarsal bones (20 %), metatarsals (20 %), femur (11 %), fibula (7 %), and pelvis (7 %) [22, 23]. In addition to the increased incidence of stress fractures in women, they tend to show a different distribution of injury, with the female pelvis and metatarsals more common, and the fibula less affected [24]. For foot and ankle overuse injuries, other potential contributing factors include malalignments (hyper/hypo-pronation, pes planus/cavus, forefoot or hindfoot varus/valgus, tibia vara, genu valgum/varum), limb length discrepancies, tarsal coalition, previous surgeries or trauma to the same or opposite limb, joint laxity or instability, and muscles weakness or imbalance [25]. All of these factors can alter the complex biomechanics and weight-bearing dynamics of the lower extremity and place undo stresses on one bone or set of bones to compensate for these alignment abnormalities or other deficiencies.

Upper extremity fatigue fractures are uncommon, but can occur, particularly with gymnastics, weightlifting, and throwing sports, such as baseball or softball [26]. Reported upper extremity stress injury sites include the clavicle, scapula, first rib, proximal humeral physis ("little leaguer's shoulder") or shaft, medial humeral epicondyle ("little leaguer's elbow"), olecranon, distal radial physis ("gymnast's wrist"), and rarely the carpal (scaphoid, hamate, triquetrum) or metacarpal bones [26].

Insufficiency fractures

Insufficiency fractures are the result of normal loading upon abnormally weakened bone. Several predisposing factors have been identified as the cause of insufficiency fractures with the common entity often being osteoporosis (primary or secondary). Other risk factors include rheumatoid arthritis, metabolic bone disease, neurological disorders, prior irradiation, total hip replacement, corticosteroid therapy, high-dose fluoride therapy, and bisphosphonate therapy, among others [6, 7, 25, 27]. In these situations, bone elasticity and mineral content are compromised.

Osteocyte lacunae demonstrate increased mineralization and sensitivity to mechanical stress as well as increased activation of bone remodeling in osteoporotic patients, ultimately leading to an equilibrium imbalance favoring bone resorption over bone formation [28, 29]. Biomechanical studies have demonstrated that cortical porosity of 20 % can decrease bone strength, and in patients over 65 years old, the average cortical porosity is 46 % [30]. Muscles normally absorb some of the normal mechanical stress, providing a protective effect to the adjacent bone. Muscle atrophy is often encountered in the elderly, and with marked sarcopenia, this protective effect is lost [31].

As a result of the abovementioned etiologies, elderly and post-menopausal women are most at risk for developing insufficiency fractures [6]. These fractures typically involve the spine (vertebral compression fractures), sacrum or pelvis (Fig. 1), lateral femoral neck, or subchondral regions of the femoral head or medial femoral condyle of the knee. Subchondral insufficiency fractures of the knee (formerly known as spontaneous osteonecrosis of the knee or SONK) are also three times more common in women and are associated with meniscal tears in up to 80 % of patients [32, 33].

Bisphosphonate-related atypical subtrochanteric femoral fractures

Bisphosphonates are synthetic analogues of inorganic pyrophosphate and potently inhibit bone resorption via the induction of osteoclast apoptosis and enhancement of secondary mineralization of bone, leading to increased osseous density. Bisphosphonate use has become widespread for the treatment of osteoporosis, hypercalcemia, Paget disease, and more recently pediatric diseases such as osteogenesis imperfecta, juvenile osteoporosis, and fibrous dysplasia [34, 35].

However, bisphosphonates can induce a relative suppression of bone turnover in some areas, particularly the jaw and the subtrochanteric femur. Long-term use can lead to quantitatively harder osseous matrix, but one that is inherently more brittle and less resilient to microtrauma, resulting in osteonecrosis of the jaw or atypical femoral subtrochanteric insufficiency fractures [36–38]. The incidence of atypical femoral subtrochanteric fractures in patients on bisphosphonate therapy for more than 3 years may be as high as 2 % [39, 40]. These may be bilateral in up to 55 % of cases [41].

Clinical presentation

Stress fractures almost universally present with pain upon activity and point tenderness. The pain is relieved with rest and worsens when the activity is continued. Typically, the presentation occurs when there has been a change in intensity of the activity, be it an increased vigor with which an athlete is training or the "weekend warrior" who only intermittently engages in strenuous activity without regular training [6]. Stress fractures can occur in almost any bone, although over 95 % of stress (fatigue) fractures occur in the lower extremities [42].

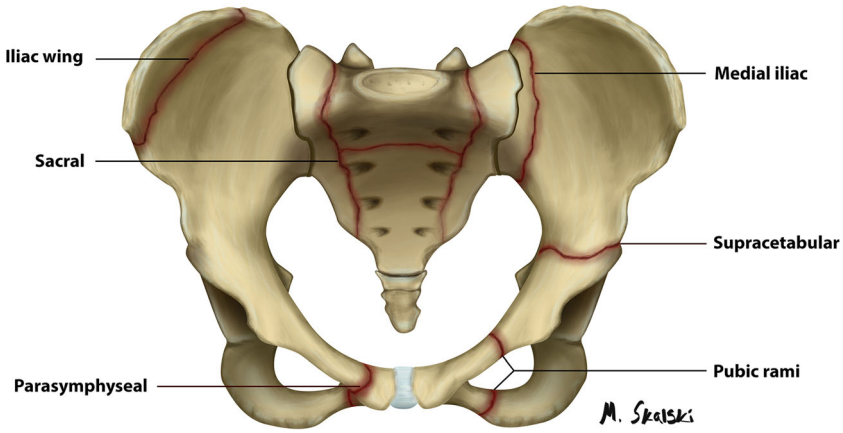

Fig. 1 Illustration demonstrating the common sites of insufficiency fractures involving the sacrum and pelvis

Furthermore, as the vast majority of stress reactions occur in the tibia, the unique entity of the medial tibial stress syndrome has been recognized as a manifestation of stress injury along a spectrum of commonly known terms such as growing pains, shin splints, and overt stress fractures [43].

Insufficiency fractures of the pelvis frequently present as low back, buttock, and groin pain in the elderly [6, 27]. Subchondral insufficiency fractures may present with sudden onset of severe pain in the absence of or following only minor trauma and, therefore, may present in an emergency setting.

Imaging

The plain radiograph is first line for imaging of musculoskeletal injuries, pain, and suspicion of a stress fracture. Radiographs are insensitive to early stress fracture and particularly difficult to diagnosis in the setting of osteopenia. Nonetheless, when present, a stress fracture may reveal the following: subtle linear sclerosis (often perpendicular to major trabeculae), focal endosteal or periosteal reaction, and fracture through one cortex with superimposed periosteal reaction (Fig. 2a) [6].

MR imaging is extremely sensitive (sensitivity 100 %, specificity 85 %), although typically a second-line modality, obtained when radiographs are normal, pain is of unknown etiology, or in athletes requiring a definitive diagnosis. A linear hypointense fracture line on T1-weighted and T2-weighted images with adjacent bone marrow and soft tissue hyperintensity on T2-fat saturated or short tau inversion recovery (STIR) sequences (edema) are typical findings (Fig. 2b). Periosteal new bone will demonstrate low signal on all sequences, and adjacent soft tissue edema may also be present.

MR imaging findings of medial tibial stress syndrome can be classified into discrete grades based on fluid-sensitive and T1-weighted characteristics of the stress injury, as first described by Fredericson et al. (Table 2, Fig. 3) [44]. Kijowski et al. expanded on this topic with the aim of determining the clinical significance of the imaging findings [45]. Grade 1 imaging features resulted in an estimated time of return to sports activity of 2–3 weeks, whereas grades 2 through 4a

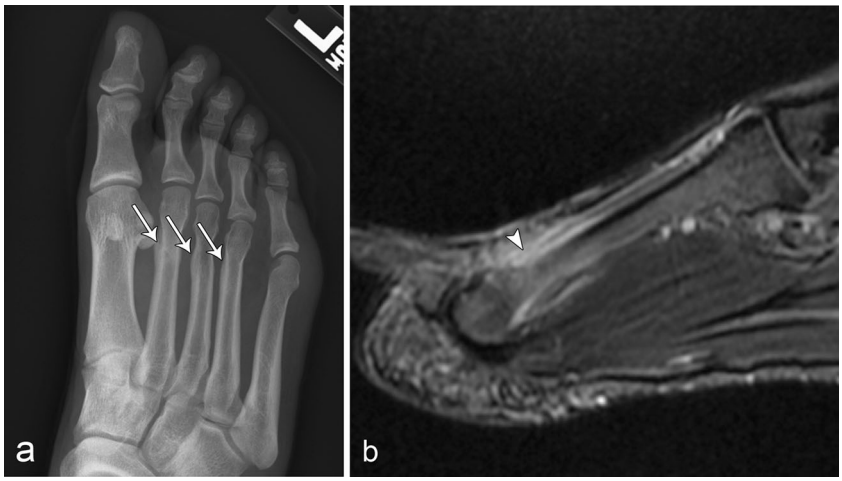

Fig. 2 A 22-year-old female basketball player with left foot pain. Oblique radiograph (**a**) demonstrates focal periosteal reaction of the 2nd, 3rd, and 4th metatarsal shafts, consistent with stress injuries (*arrows*). Sagittal STIR MRI of the 2nd metatarsal (**b**) shows periosteal and marrow edema (arrowhead)

Table 2 Fredericson MRI classification for medial tibial stress syndrome

Grade	Periosteal edema	Marrow STIR SI	Marrow T1 SI	Intracortical signal
0	No	Normal	Normal	Normal
1	Yes	Normal	Normal	Normal
2	Yes	High	Normal	Normal
3	Yes	High	Low	Normal
4a	Yes	High	Low	Focal abnormality
4b	Yes	High	Low	Linear fracture

injuries resulted in longer average times to return to activity of 6–7 weeks. Frank stress fractures (grade 4b) resulted in average time to return to activity of 9–10 weeks, with a wide range. This establishes the importance of early detection of these injuries for proper treatment and may ultimately prolong the career of the athlete [43, 45].

MRI is also important for diagnosing subchondral insufficiency fractures, which are not apparent on radiographs unless there is linear subchondral lucency or collapse. MRI will show a convex curvilinear hypointensity paralleling the articular surface with prominent adjacent bone marrow edema on fluid-sensitive sequences, often extending into the metaphysis (Fig. 4) [46]. In some cases, the curvilinear hypointensity may be subtle or inapparent, particularly if images were obtained sub-optimally with a low-field strength scanner, with a large field of view, or without a dedicated joint-specific coil, and thus only the bone marrow edema may be appreciated. In those cases, transient bone marrow edema syndrome or early avascular necrosis should also be considered in the differential diagnosis. As such, short-term follow-up MRI to document resolution after limited weight-bearing and other conservative therapy should be obtained. Newer techniques such as dynamic post-contrast MR perfusion imaging may allow earlier differentiation from avascular necrosis [47].

Computed tomography (CT) is useful for identification of longitudinal fracture lines and has the added benefit of orthogonal reformations. In particular, when osteoid osteoma is on the differential diagnosis, cross-sectional CT will reveal the central lucent nidus of an osteoid osteoma, while a linear

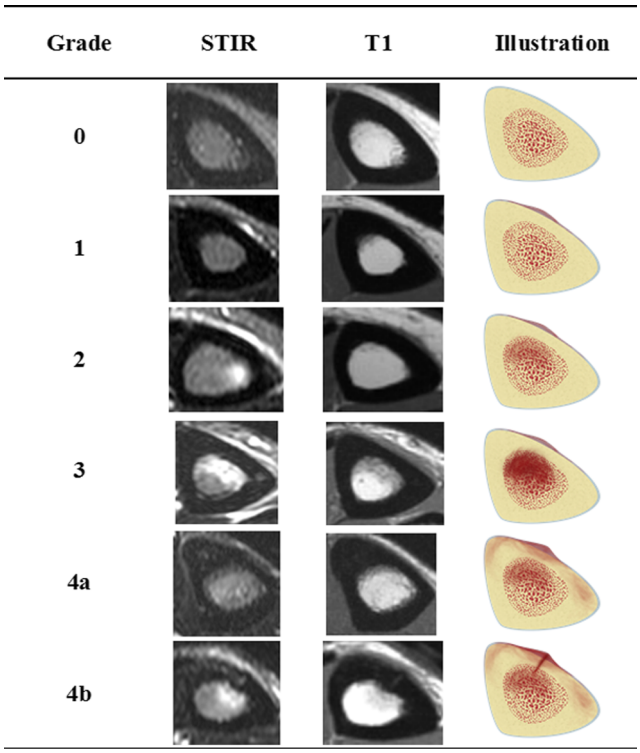

Fig. 3 Fredericson classification of medial tibial stress syndrome with representative axial STIR and T1 MR images and illustrations

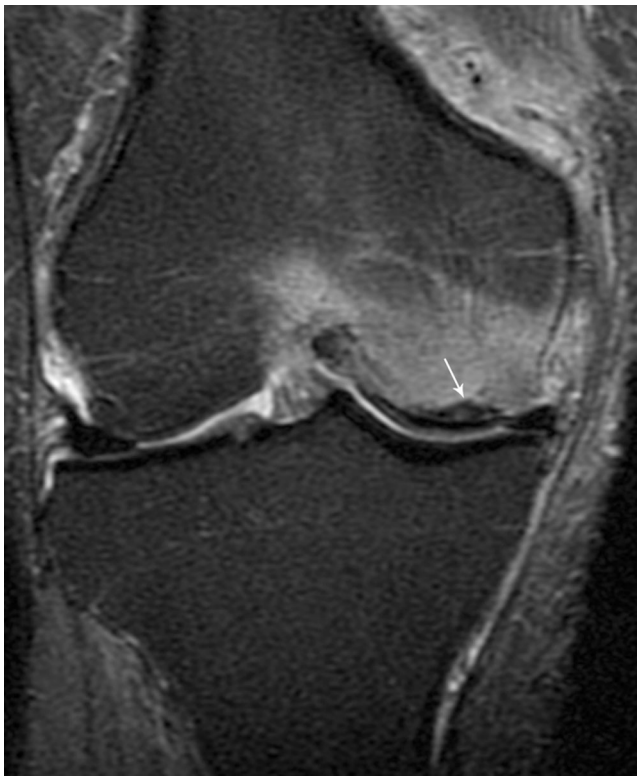

Fig. 4 A 68-year-old man with recent onset knee pain. Coronal STIR MR image demonstrates subchondral curvilinear hypointensity (*arrow*) with prominent adjacent bone marrow edema extending close to the physeal scar, consistent with a subchondral insufficiency fracture

fracture line will be apparent in the case of a fatigue fracture. Additionally, CT is useful in the evaluation of stress injury of the spine. Often, the fracture line of par interarticularis stress fractures (spondylolysis) can be seen on CT but remains occult on radiograph and difficult to visualize on MR imaging [48]. Nevertheless, CT can provide false reassurance regarding the activity of a stress injury. Chronic lesions may have the appearance of bone turnover on CT, while their true activity and edema cannot be assessed, as is possible with bone scintigraphy and MRI, respectively [48]. CT is insensitive for the evaluation of transverse fractures; however, reformations in multiple planes may be useful.

Ultrasound is increasingly becoming a readily available and efficient tool for evaluation of stress fractures. Primarily limited to the evaluation of more superficial bones, ultrasound can evaluate the hyperechoic superficial margins of cortical bone, revealing cortical buckling and surrounding hypoechoic callus. Although not validated, Power Doppler technology can be used to evaluate vascularity, an increase in which may suggest acuity of bone injury [48].

Many initial studies have reviewed the use of bone scintigraphy in the evaluation of stress injuries and three-phase Technetium-99m-methylene diphosphonate (Tc-99m-MDP) bone scans are often considered the gold standard. The modality is excellent for its sensitivity in detecting abnormal metabolic bone activity; however, it is inherently weak in its specificity, with up to 40 % of increased tracer uptake occurring at asymptomatic sites [49]. A three-phase bone scan is performed consisting of an immediate post-injection angiographic phase, a blood pool phase, and delayed 2- to 4-h imaging. Activity is demonstrated in areas of new bone formation at sites of healing stress fractures where there is osteoblastic activity occurring. With medial tibial stress syndrome, increased uptake may only be seen on the delayed phase [50]. Insufficiency fractures may be asymptomatic and found incidentally on bone scintigraphy or plain films [23, 51]. 18F-fluorodeoxyglucose (FDG) positron emission tomography (PET) or PET/CT can also demonstrate activity at stress fracture sites. Some patterns of uptake, such as the "Honda sign" for sacral insufficiency fractures can be diagnostic, with sensitivity and positive predictive value of up to 96 and 92 %, respectively (Fig. 5) [52, 53].



Fig. 5 An 83 year-old-man with prostate cancer and history of pelvic radiation therapy. Tc99m-MDP bone scan demonstrates typical pattern of butterfly or H-shaped sacral uptake consistent with the "Honda sign," indicating sacral insufficiency fractures

Of all of these useful imaging modalities, MRI provides the most comprehensive evaluation of stress injuries and reveals both functional and morphologic information about the bone [48]. For insufficiency fractures of the pelvis and proximal femur, MRI has been shown to be superior to CT, with sensitivities of 99 and 69 %, respectively [54]. Table 3 summarizes the advantages and typical features of stress fracture for each imaging modality.

Bisphosphonate-related atypical subtrochanteric femoral fractures

These fractures may be subtle on radiographs, beginning with focal lateral cortical thickening progressing to development of focal cortical lucency and ultimately a discrete

Table 3 Summary of stress fracture imaging

Imaging modality	Findings and advantages/limitations
Radiographs	Linear sclerosis, often perpendicular to major trabeculae
	Focal endosteal/periosteal reaction Fracture through one cortex with periosteal reaction
MRI	Linear hypointense fracture line on all pulse sequences Adjacent bone marrow and soft tissue edema
	Sensitivity 100%, specificity 85%
CT	Optimal for identifying longitudinal fracture line Can miss transverse fracture without reformations
Ultrasound	Cortical step-off with adjacent hypoechoic callus
	Superficial bones, Power Doppler for vascularity
Bone scan	Increased tracer uptake on all three phases
	Sensitive, but has potential for false positives

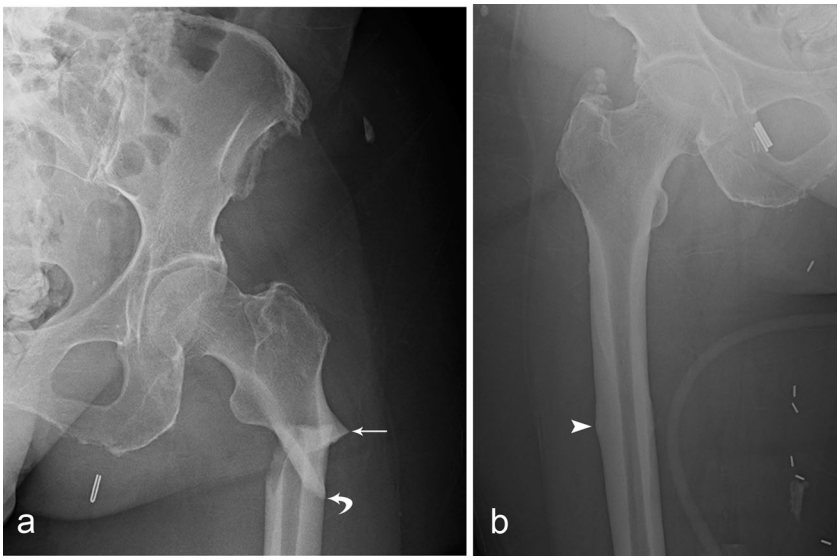

Fig. 6 An 80-year-old woman with acute left hip pain after minimal trauma. AP radiograph of the left hip (**a**) demonstrates a non-comminuted subtrochanteric fracture of the left proximal femur with lateral cortical beaking (*arrow*) and medial spike (*curved arrow*). A history of long-term bisphosphonate use was elicited. AP radiograph of the right proximal femur (**b**) demonstrates focal lateral cortical thickening of the subtrochanteric femoral diaphysis with a subtle transverse linear lucency (*arrowhead*; "*dreaded black line*"). The patient subsequently received prophylactic intramedullary rod fixation of the right femur in addition to open reduction and internal fixation of the left femur fracture

transverse lucent linear fracture line [38]. This finding is sometimes referred to as the "dreaded black line," given the high risk that this incomplete lateral cortical fracture will progress to a complete fracture if left untreated. These findings may be at the edge or just beyond the visualized field of view of pelvic or hip radiographs. Beaking of the lateral cortex at the fracture margin, minimal comminution and the presence of a medial spike can help to differentiate a completed bisphosphonate-related fracture from a post-traumatic one (Fig. 6) [55]. MRI may demonstrate periosteal reaction and marrow edema before radiographic findings are apparent, and cortical abnormalities may also be identified earlier on MRI [56].

Differential diagnosis

A careful review of the history and clinical exam is key to the effective interpretation of potential stress injuries. On conventional radiographs, the differential diagnosis of stress injuries includes normal cortical thickening, normal nutrient artery channel, osteomyelitis/Brodie abscess, osteoid osteoma, other neoplasms (e.g., surface osteosarcoma or metastasis), osteitis pubis, and avascular necrosis [25]. This differential diagnosis is summarized in Table 4.

Bone marrow edema seen on MR is decidedly non-specific, but yet very sensitive for very early stress response. The clinical significance of edema on MR imaging has yet to be completely defined, as the underlying histological etiology of the change in signal intensity is still unclear [57]. Bone marrow edema can be seen in the setting of neoplasm, infection, fracture, in the feet of runners and non-runners, and as an incidental finding in asymptomatic adults and children [32, 57, 58]. Therefore, when present, bone marrow edema needs to be interpreted in the correct clinical context. A key clinical feature to differentiate neoplasm and infection from stress injury is that the former will present with pain upon activity and

Table 4 Differential diagnosis for stress fractures at imaging

Finding	Differential diagnosis
Focal cortical thickening	Normal variant, osteoid osteoma, chronic osteomyelitis/Brodie abscess, stress loading (arthroplasties)
Periosteal reaction	Infection, surface osteosarcoma, hypertrophic osteoarthropathy
Linear lucency	Normal nutrient vessel channel, osteomalacia (Looser zones)
Sclerosis	Osteitis condensans ilii, osteitis pubis, chronic osteomyelitis
Bone marrow edema	Transient bone marrow edema syndrome, avascular necrosis, osteomyelitis, tumor

Table 5 Comparison of sites of stress fractures based on the likelihood of uncomplicated healing with conservative management only

High risk	Medium risk	Low risk
Femoral neck tension fracture	Femoral shaft	Femoral neck compression fracture
Transverse patellar fracture	Pelvis	Longitudinal patellar fracture
Mid anterior tibial shaft fracture	Posteromedial tibia shaft fracture	
Medial malleolus		Fibula/lateral malleolus
Talus and navicular		Calcaneus and Cuboid
Proximal 2nd metatarsal and hallux sesamoids	Proximal 5th metatarsal	2nd–4th metatarsal shafts

rest, while stress fractures typically present as pain with activity, absent, or decreased with rest [25].

Management

Fatigue fractures

Treatment of a fatigue fracture is generally conservative [59]. Recommendations include protected or limited weight bearing, ice, and physical therapy. Depending on the location of the stress fracture, surgical therapy is sometimes recommended. It is important to differentiate between low-risk and high-risk fatigue fractures and alert the referring orthopedist when such injuries are discovered.

High- versus low-risk fractures are stratified by location based on the likelihood of uncomplicated healing with conservative management alone (Table 5, Fig. 7). *Low-risk* sites include the second through fourth metatarsal shafts, fibula/lateral malleolus, calcaneus, cuboid, cuneiforms, and medial femoral neck compression fractures. *Medium-risk* sites include the pelvis, femoral shaft, posteromedial tibia, medial malleolus, and proximal fifth metatarsal. *High-risk* sites include the pars interarticularis of the lumbar spine, femoral head, lateral femoral neck tension fractures, patella (transverse fractures), anterior cortex of the tibia, and several sites within the foot: talar body, navicular, proximal second metatarsal, and great toe or hallux sesamoids [60–62]. Orthopedic or sports medicine consultation should be obtained when a high-risk site is involved.

Biopsy should be avoided, as the sample may mimic an aggressive bone tumor such as parosteal osteosarcoma due to the osteoblastic reparative callus, and be histologically confusing. The biopsy also further weakens the bone, increasing the likelihood the stress injury will progress to an outright fracture [6].

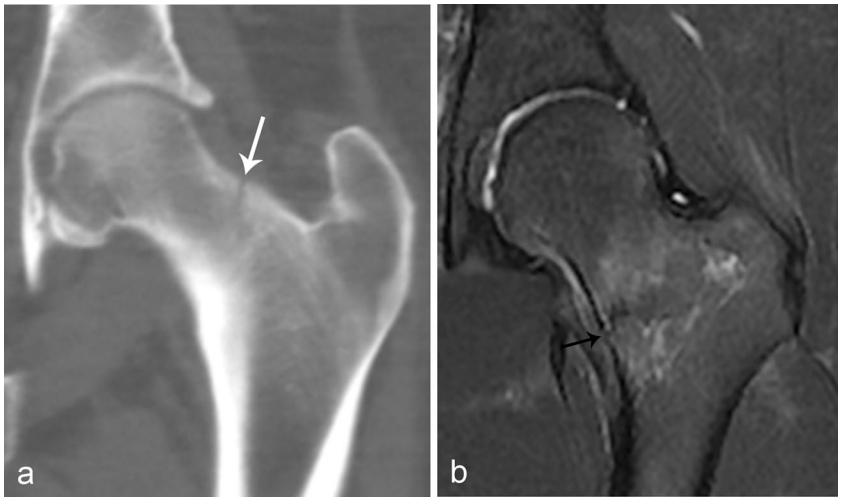

Fig. 7 Femoral neck tension versus compression fractures. Coronal CT reconstruction of the left hip (**a**) in a 52-year-old woman with pain demonstrates a linear lucency of the superolateral femoral neck (*white arrow*), consistent with a tension fracture. Coronal STIR MR image (**b**) in a 23-year-old male runner with pain demonstrates a subtle transverse linear hypointensity with adjacent bone marrow edema of the inferomedial femoral neck (*black arrow*), consistent with a compression fracture. Tension fractures are high-risk fractures and typically require fixation to heal. Compression fractures are low-risk fractures that generally heal well with rest

Insufficiency fractures

Typical

Ideally, strategies focusing on identifying at risk patients and applying preventative measures should be applied before insufficiency fractures occur. A bone mineral density (BMD) test using dual-energy X-ray absorptiometry (DEXA) scan can identify osteopenic or osteoporotic patients. Secondary causes of osteoporosis should be excluded. Medical therapy with bisphosphonates, hormone replacement therapy, calcitonin, or other drugs can be considered. Fall prevention steps should also be undertaken, and education, behavioral modification, exercise classes, or a multidisciplinary program may help, although their role is controversial.

Once insufficiency fractures occur, treatment will depend on location, fracture extent and displacement, the patient's functional status, and co-existing diseases. Osteopenia can complicate both fracture healing and treatment, with poor bone stock compromising internal fixation and screw purchase, increasing the risk of non-union. Augmentation with methylmethacrylate cement may be useful in some instances, particularly in the spine, sacrum, and pelvis [63]. Bone graft or bone graft substitutes may also be used to help promote fracture healing.

Subchondral insufficiency fractures

Subchondral insufficiency fractures are treated based on their radiographic classification: Stage 1 has normal radiographs, stage 2 demonstrates mild flattening of the weight bearing surface, stage 3 shows subchondral collapse, and stage 4 has secondary degenerative changes [32]. Early-stage (stages 1 and 2) lesions are treated with conservative management with the hope of spontaneous recovery, while late-stage (stages 3 and 4) lesions usually necessitate future arthroplasty.

Bisphosphonate-related atypical subtrochanteric femoral fractures

Once a bisphosphonate-related atypical insufficiency fracture is recognized, conservative measures such as limited weight-bearing and serial radiographs are performed [39]. In addition, radiographs of the opposite femur should be obtained, as these can be bilateral in up to 55 % of cases [41]. Given the evidence establishing the efficacy of bisphosphonates and the reported low fracture occurrence rate of 1.46 per 1000 patients treated per year, no agreed upon statement for withdrawal of the medication have been proposed [64]. However, recent clinical evidence supports a drug holiday of 3–5 years in asymptomatic patients demonstrating an improved T score of −2.0 or higher who have had no history of typical osteoporotic insufficiency fractures [65]. Because there is a propensity for delayed union in bisphosphonate-related atypical femoral fractures, there has been increasing clinical interest in proactively treating incipient or incomplete cortical injuries with a variety of supplemental measures, including recombinant parathyroid hormone (e.g., teriparatide) and low-intensity pulsed ultrasound [38]. Furthermore, given the subsequent increased morbidity inherent in cases of delayed union, some centers advocate prophylactic internal fixation of stress injuries when detected at radiologic screening, even in the absence of a frank fracture plane [66].

Conclusion

Stress fractures are an important cause of pain and morbidity, and the emergency radiologist should be familiar with their imaging features, which can be subtle or inapparent, particularly on radiographs, as well as having a basic understanding of the pathophysiology, differential diagnosis, and further workup and treatment. Stress fractures include both fatigue fractures (abnormal load on normal bone) and insufficiency fractures (normal load on abnormal or osteopenic bone). Fatigue fractures are common overuse injuries most often seen in athletes, particularly runners, and most often involve the lower extremities, particularly the foot and tibia (medial tibial stress syndrome). Insufficiency fractures are common in elderly osteoporotic populations, often involving the pelvis. Important subtypes to recognize are subchondral insufficiency fractures, most commonly involving the medial femoral condyle or femoral head, and bisphosphonate-related atypical subtrochanteric femoral fractures.

Acknowledgments We would like to thank Robert W. Henderson, MD for contributing the case of a sacral insufficiency fracture on PET-CT (Fig. 7c). We would also like to honor the memory of Deborah M. Forrester, MD, who was a co-author on the educational exhibit from which this paper derives and served as such an inspirational teacher and mentor to us during her long and brilliant career.

Compliance with Ethical Standards

Conflict of interest The authors declare that they have no conflict of interest.

Grants The authors did not receive any grants.

References

1. Breithaupt M (1855) The pathology of the human foot [in German]. Medizin Zeitung 24:169–175
2. Pepper M, Akuthota V, McCarty EC (2006) The pathophysiology of stress fractures. Clin Sports Med 25(1):1–16. doi:10.1016/j.csm.2005.08.010, **vii**

3. Rosen CJ, American Society for Bone and Mineral Research (2008) Primer on the metabolic bone diseases and disorders of mineral metabolism, 7th edn. American Society for Bone and Mineral Research, Washington, D.C
4. Simon SR, American Academy of Orthopaedic Surgeons (1994) Orthopaedic basic science. American Academy of Orthopaedic Surgeons, Rosemont, Ill
5. Chamay A, Tschantz P (1972) Mechanical influences in bone remodeling. Experimental research on Wolff's law. J Biomech 5(2): 173–180
6. Daffner RH, Pavlov H (1992) Stress fractures: current concepts. AJR Am J Roentgenol 159(2):245–252. doi:10.2214/ajr.159.2.1632335
7. Krestan C, Hojreh A (2009) Imaging of insufficiency fractures. Eur J Radiol 71(3):398–405. doi:10.1016/j.ejrad.2008.04.059
8. Kadel NJ, Teitz CC, Kronmal RA (1992) Stress fractures in ballet dancers. Am J Sports Med 20(4):445–449
9. Bennell KL, Malcolm SA, Thomas SA, Wark JD, Brukner PD (1996) The incidence and distribution of stress fractures in competitive track and field athletes. A twelve-month prospective study. Am J Sports Med 24(2):211–217
10. Bennell KL, Malcolm SA, Thomas SA, Reid SJ, Brukner PD, Ebeling PR, Wark JD (1996) Risk factors for stress fractures in track and field athletes. A twelve-month prospective study. Am J Sports Med 24(6):810–818
11. Warden SJ, Burr DB, Brukner PD (2006) Stress fractures: pathophysiology, epidemiology, and risk factors. Curr Osteoporos Rep 4(3):103–109
12. Rigotti NA, Nussbaum SR, Herzog DB, Neer RM (1984) Osteoporosis in women with anorexia nervosa. N Engl J Med 311(25):1601–1606. doi:10.1056/NEJM198412203112503
13. Zernicke RF, McNitt-Gray J, Otis C, Loitz B, Salem G, Finerman G (1994) Stress fractures risk assessment among elite collegiate women runners. J Biomech 27(6):854
14. Rigotti NA, Neer RM, Skates SJ, Herzog DB, Nussbaum SR (1991) The clinical course of osteoporosis in anorexia nervosa. A longitudinal study of cortical bone mass. JAMA 265(9):1133–1138
15. Winfield AC, Moore J, Bracker M, Johnson CW (1997) Risk factors associated with stress reactions in female Marines. Mil Med 162(10):698–702
16. Barrow GW, Saha S (1988) Menstrual irregularity and stress fractures in collegiate female distance runners. Am J Sports Med 16(3): 209–216
17. Nattiv A, Armsey TD Jr (1997) Stress injury to bone in the female athlete. Clin Sports Med 16(2):197–224
18. Johnson AW, Weiss CB Jr, Wheeler DL (1994) Stress fractures of the femoral shaft in athletes—more common than expected. A new clinical test. Am J Sports Med 22(2):248–256
19. Goldberg B, Pecora C (1994) Stress fractures: a risk of increased training in freshman. Phys Sports Med 22:68–78
20. Bell DG, Jacobs I (1986) Electro-mechanical response times and rate of force development in males and females. Med Sci Sports Exerc 18(1):31–36
21. Miller GJ, Purkey WW Jr (1980) The geometric properties of paired human tibiae. J Biomech 13(1):1–8
22. Csizy M, Babst R, Fridrich KS (2000) "Bone tumor" diagnostic error in stress fracture of the medial tibial plateau. Unfallchirurg 103(11):993–995
23. Wall J, Feller JF (2006) Imaging of stress fractures in runners. Clin Sports Med 25(4):781–802. doi:10.1016/j.csm.2006.06.003
24. Pećina M, Bojanić I (2004) Overuse injuries of the musculoskeletal system, 2nd edn. CRC Press, Boca Raton
25. Muthukumar T, Butt SH, Cassar-Pullicino VN (2005) Stress fractures and related disorders in foot and ankle: plain films, scintigraphy, CT, and MR Imaging. Semin Musculoskelet Radiol 9(3):210–226. doi:10.1055/s-2005-921941
26. Anderson MW (2006) Imaging of upper extremity stress fractures in the athlete. Clin Sports Med 25(3):489–504. doi:10.1016/j.csm.2006.02.006, **vii**
27. Davies AM (1990) Stress lesions of bone. Curr Imaging 2:209–216
28. Carpentier VT, Wong J, Yeap Y, Gan C, Sutton-Smith P, Badiei A, Fazzalari NL, Kuliwaba JS (2012) Increased proportion of hypermineralized osteocyte lacunae in osteoporotic and osteoarthritic human trabecular bone: implications for bone remodeling. Bone 50(3):688–694. doi:10.1016/j.bone.2011.11.021
29. Syed FA, Hoey KA (2010) Integrative physiology of the aging bone: insights from animal and cellular models. Ann N Y Acad Sci 1211:95–106. doi:10.1111/j.1749-6632.2010.05813.x
30. Zebaze RM, Ghasem-Zadeh A, Bohte A, Iuliano-Burns S, Mirams M, Price RI, Mackie EJ, Seeman E (2010) Intracortical remodelling and porosity in the distal radius and post-mortem femurs of women: a cross-sectional study. Lancet 375(9727):1729–1736. doi:10.1016/S0140-6736(10)60320-0
31. Iundusi R, Scialdoni A, Arduini M, Battisti D, Piperno A, Gasbarra E, Tarantino U (2013) Stress fractures in the elderly: different pathogenetic features compared with young patients. Aging Clin Exp Res 25(Suppl 1):S89–S91. doi:10.1007/s40520-013-0105-y
32. Yamamoto T, Bullough PG (2000) Spontaneous osteonecrosis of the knee: the result of subchondral insufficiency fracture. J Bone Joint Surg Am 82(6):858–866
33. Robertson DD, Armfield DR, Towers JD, Irrgang JJ, Maloney WJ, Harner CD (2009) Meniscal root injury and spontaneous osteonecrosis of the knee: an observation. J Bone Joint Surg Br 91(2):190–195. doi:10.1302/0301-620X.91B2.21097
34. Fleisch H (2002) Development of bisphosphonates. Breast Cancer Res 4(1):30–34
35. Shoemaker LR (1999) Expanding role of bisphosphonate therapy in children. J Pediatr 134(3):264–267
36. Lenart BA, Lorich DG, Lane JM (2008) Atypical fractures of the femoral diaphysis in postmenopausal women taking alendronate. N Engl J Med 358(12):1304–1306. doi:10.1056/NEJMc0707493
37. Lenart BA, Neviaser AS, Lyman S, Chang CC, Edobor-Osula F, Steele B, van der Meulen MC, Lorich DG, Lane JM (2009) Association of low-energy femoral fractures with prolonged bisphosphonate use: a case control study. Osteoporos Int 20(8): 1353–1362. doi:10.1007/s00198-008-0805-x
38. Rheinboldt M, Harper D, Stone M (2014) Atypical femoral fractures in association with bisphosphonate therapy: a case series. Emerg Radiol 21(5):557–562. doi:10.1007/s10140-014-1215-3
39. La Rocca VR, Rosenberg ZS, Allison MB, Im SA, Babb J, Peck V (2012) Frequency of incomplete atypical femoral fractures in asymptomatic patients on long-term bisphosphonate therapy. AJR Am J Roentgenol 198(5):1144–1151. doi:10.2214/AJR.11.7442
40. Allison MB, Markman L, Rosenberg Z, Vieira RL, Babb J, Tejwani N, Peck V (2013) Atypical incomplete femoral fractures in asymptomatic patients on long term bisphosphonate therapy. Bone 55(1): 113–118. doi:10.1016/j.bone.2013.03.018
41. Chan SS, Rosenberg ZS, Chan K, Capeci C (2010) Subtrochanteric femoral fractures in patients receiving long-term alendronate therapy: imaging features. AJR Am J Roentgenol 194(6):1581–1586. doi:10.2214/AJR.09.3588
42. Berger FH, de Jonge MC, Maas M (2007) Stress fractures in the lower extremity. The importance of increasing awareness amongst radiologists. Eur J Radiol 62(1):16–26. doi:10.1016/j.ejrad.2007.01.014
43. Swischuk LE, Jadhav SP (2014) Tibial stress phenomena and fractures: imaging evaluation. Emerg Radiol 21(2):173–177. doi:10.1007/s10140-013-1181-1
44. Fredericson M, Bergman AG, Hoffman KL, Dillingham MS (1995) Tibial stress reaction in runners. Correlation of clinical symptoms and scintigraphy with a new magnetic resonance imaging grading system. Am J Sports Med 23(4):472–481

45. Kijowski R, Choi J, Shinki K, Del Rio AM, De Smet A (2012) Validation of MRI classification system for tibial stress injuries. AJR Am J Roentgenol 198(4):878–884. doi:10.2214/AJR.11.6826
46. Yamamoto T, Bullough PG (2000) Subchondral insufficiency fracture of the femoral head and medial femoral condyle. Skeletal Radiol 29(1):40–44
47. Mueller D, Schaeffeler C, Baum T, Walter F, Rechl H, Rummeny EJ, Woertler K (2014) Magnetic resonance perfusion and diffusion imaging characteristics of transient bone marrow edema, avascular necrosis and subchondral insufficiency fractures of the proximal femur. Eur J Radiol 83(10):1862–1869. doi:10.1016/j.ejrad.2014.07.017
48. Sofka CM (2006) Imaging of stress fractures. Clin Sports Med 25(1):53–62. doi:10.1016/j.csm.2005.08.009, **viii**
49. Bennell K, Matheson G, Meeuwisse W, Brukner P (1999) Risk factors for stress fractures. Sports Med 28(2):91–122
50. Deutsch AL, Coel MN, Mink JH (1997) Imaging of stress injuries to bone. Radiography, scintigraphy, and MR imaging. Clin Sports Med 16(2):275–290
51. Nielens H, Devogelaer JP, Malghem J (1994) Occurrence of a painful stress fracture of the femoral neck simultaneously with six other asymptomatic localizations in a runner. J Sports Med Phys Fitness 34(1):79–82
52. Joshi P, Lele V, Gandhi R, Parab A (2012) Honda sign on 18-FDG PET/CT in a case of lymphoma leading to incidental detection of sacral insufficiency fracture. J Clin Imaging Sci 2:29. doi:10.4103/2156-7514.96544
53. Fujii M, Abe K, Hayashi K, Kosuda S, Yano F, Watanabe S, Katagiri S, Ka WJ, Tominaga S (2005) Honda sign and variants in patients suspected of having a sacral insufficiency fracture. Clin Nucl Med 30(3):165–169
54. Cabarrus MC, Ambekar A, Lu Y, Link TM (2008) MRI and CT of insufficiency fractures of the pelvis and the proximal femur. AJR Am J Roentgenol 191(4):995–1001. doi:10.2214/AJR.07.3714
55. Rosenberg ZS, La Rocca VR, Chan SS, Babb J, Akyol Y, Rybak LD, Moore S, Bencardino JT, Peck V, Tejwani NC, Egol KA (2011) Bisphosphonate-related complete atypical subtrochanteric femoral fractures: diagnostic utility of radiography. AJR Am J Roentgenol 197(4):954–960. doi:10.2214/AJR.10.6262
56. Png MA, Koh JS, Goh SK, Fook-Chong S, Howe TS (2012) Bisphosphonate-related femoral periosteal stress reactions: scoring system based on radiographic and MRI findings. AJR Am J Roentgenol 198(4):869–877. doi:10.2214/AJR.11.6794
57. Zanetti M, Steiner CL, Seifert B, Hodler J (2002) Clinical outcome of edema-like bone marrow abnormalities of the foot. Radiology 222(1):184–188. doi:10.1148/radiol.2221010316
58. MacDougall L, Conway WF (1996) Controversies in magnetic resonance imaging of the hip. Top Magn Reson Imaging 8(1):44–50
59. Raasch WG, Hergan DJ (2006) Treatment of stress fractures: the fundamentals. Clin Sports Med 25(1):29–36. doi:10.1016/j.csm.2005.08.013, **vii**
60. Debnath UK, Freeman BJ, Grevitt MP, Sithole J, Scammell BE, Webb JK (2007) Clinical outcome of symptomatic unilateral stress injuries of the lumbar pars interarticularis. Spine (Phila Pa 1976) 32(9):995–1000. doi:10.1097/01.brs.0000260978.10073.90
61. Boden BP, Osbahr DC (2000) High-risk stress fractures: evaluation and treatment. J Am Acad Orthop Surg 8(6):344–353
62. Fredericson M, Jennings F, Beaulieu C, Matheson GO (2006) Stress fractures in athletes. Top Magn Reson Imaging 17(5):309–325. doi:10.1097/RMR.0b013e3180421c8c
63. Lyders EM, Whitlow CT, Baker MD, Morris PP (2010) Imaging and treatment of sacral insufficiency fractures. AJNR Am J Neuroradiol 31(2):201–210. doi:10.3174/ajnr.A1666
64. Kim SR, Ha YC, Park YG, Lee SR, Koo KH (2011) Orthopedic surgeon's awareness can improve osteoporosis treatment following hip fracture: a prospective cohort study. J Korean Med Sci 26(11):1501–1507. doi:10.3346/jkms.2011.26.11.1501
65. Nieves JW, Cosman F (2010) Atypical subtrochanteric and femoral shaft fractures and possible association with bisphosphonates. Curr Osteoporos Rep 8(1):34–39. doi:10.1007/s11914-010-0007-2
66. Kang JS, Won YY, Kim JO, Min BW, Lee KH, Park KK, Song JH, Kim YT, Kim GH (2014) Atypical femoral fractures after anti-osteoporotic medication: a Korean multicenter study. Int Orthop 38(6):1247–1253. doi:10.1007/s00264-013-2259-9